



HISTOPATHOLOGICAL AND PHYSIOLOGICAL STUDY OF THE EFFECT OF DIFFERENT DOSES OF VITAMIN D3 ON THE KIDNEY IN FEMALE ALBINO RATS

Vian Ihsan Khasro and Mukhtar Khamis Haba

Department of Biology, College of Science for Women, University of Baghdad, Iraq

Corresponding author: Veyan.Ihsan1102a@csw.uobaghdad.edu.iq, 07738017515.

Abstract

This study was conducted to fine out the effect of different doses of vitamin D3 on the physiology and histology of the kidney in female albino rats. Vitamin D3 was administered orally to female albino rats in concentrations (5000 IU, 7500 IU, 1000 IU) for 3-6 weeks. Many physiological symptoms in the kidneys of treated female rats, which included an increase in the concentration of calcium, phosphorus, urea and creatinine in serum and decrease in serum parathyroid hormone level. Also Histological symptoms were appeared included necrosis, Hyaline Degeneration, congestion and hemorrhage in cortex and medulla. As well as vacillation case appeared in the epithelium cells of the collecting tubules, infiltration of inflammatory cells and swelling of the urinary epithelium due to degeneration and the emergence of Cystic coatings as a result of atrophy in the renal tubules in the cortex.

Keyword: vitaminD₃, Hypervitaminosis, Hypercalcemia, kidney, Rats.

Introduction

Vitamin D, also called calciferol, is a secosterol, a fat-soluble vitamin. It is necessary to develop a normal skeleton and maintain calcium balance in the body. Vitamin D can be obtained from food sources or can be synthesized in the body (Del-Valle and Heather, 2011). Vitamin D3 is the most toxic among vitamins, there is currently an increased risk of toxicity of vitamin D3 (cholecalciferol) due to its use in infant nutrition, dietary supplements and vitamin preparations (Holick and Vitamin, 2006). This may cause hypervitaminosis, which is usually iatrogenic because of its prescription in high doses by doctors without a clear diagnosis of deficiency, although vitamin D3 has a wide therapeutic area (Döneray, 2009). Where doctors recommend high daily doses of vitamin D3 for several weeks as a treatment for autoimmune diseases such as rheumatoid arthritis and chronic bone diseases such as osteoporosis and psoriasis because they are associated with low level of vitamin D3 in the blood and therefore, The rate of hypervitaminosis D3 may increase (Patel, 2007). An overdose of vitamin D3 may lead to hypervitaminosis or intoxication, although it is extremely rare in humans and animals, but hypervitaminosis D3 leads to markedly excessive calcium level in the blood leading to deposition of calcium salts in soft tissues such as kidneys, blood vessels, heart and lungs and thus It leads to calcification of tissues, which causes imbalance in the structure and function of vital organs (Chavhan, 2011). The present study used high daily concentrations of vitamin D3 not previously used by other researchers. The aim of the current study is to identify the physiological and histological effects that may be caused by excessive use or high doses of vitamin D3 on the kidneys.

Materials and Methods

Preparation of Doses

The dietary supplement vitamin D3(cholecalciferol) obtained from the Turkish company Bio-vitans, used as tablet form . Three sub-lethal concentrations were selected : [5000IU (5.71mg \ kg), 7500IU (8.57mg \ kg), 10000IU (11.42mg \ kg)]depend on the LD 50 (42.5 mg/kg) for rat females (Marshall, 1984). The amount of one dose is (0.5) ml

of vitamin D3 dissolved in corn oil, Doses were prepared by using the following formula:

$$X / \text{rat weight} = \text{dose given} / 100.$$

Experimental Animals

In this study, (48) female albino rats species *Mus musculus* (6-8 weeks) age with an average weight of (200-250 kg) were obtained from Biotechnology Research Center / Al-Nahrain University. The animals were placed in plastic cages covered with metal mesh lids with 8 rats per cage. The cage contains wooden shave. It was fed with a special diet and provided with drinking water by means of special bottles, providing the appropriate temperature and ventilation .Weights of animals were determined before and after the dose period (3-6) weeks.

Groups of Experimental Animals

The animals were divided into four groups (A, B, C, D) according to the given doses, exposed for 6 weeks orally as follows: Group A: included control animals exposed with (0.5) ml of corn oil only. Group B: exposed with (0.5) ml vitamin D3 at a concentration of 5000 IU. Group C: exposed with (0.5) ml vitamin D3 at a concentration of 7500 IU. Group D: exposed with (0.5) ml of vitamin D3 at a concentration of 1000IU

Biochemical study

Blood was drawn directly from the heart of the exposed animals by heart puncture, and collected in tubes placed by centrifuge at a rate of 2000 r / min for 10 minutes, to obtain the serum. Isolated serum from other blood components kept at 4 °C until physiological tests are performed using Siemens device/ Dimension system. The measurements were made at the Medical City \ Baghdad Teaching Hospital.

Statistical analysis

SAS (2010) was used in statistical analysis to study the effect of different factors on the studied traits, and the significant differences between the averages were compared in the least significant difference test (LSD) (SAS 2005).

Histological study

Bancroft and Steven's method (Bancroft and Stevens, 2010) was used to prepare tissue sections. The animals were sacrificed after anesthetizing them with chloroform. to remove kidney after making longitudinally incision in the abdomen and kept in the Aqueous Bouin's Solution for (22-24) hours, Then samples were transferred to 70% alcohol until the tissue sections were prepared. The slides were stained with hematoxylin-eosin. Microscopic slides were examined and photographed by using a light microscope (Olympus (Japan)) with camera (Meiji (Japan)).

Results and Discussion

Clinical signs

Toxicity of vitamin D3 had shown some side effects in the behavior of the exposed individuals. Neurological signs such as aimless running were observed, especially in the first week of the dose and increased with the duration of the dose, accompanied by a decrease in feed intake and an increase in drinking water, especially in latest weeks significantly. An increase in diuresis was also observed in some groups, especially in group D, this is attributed to the increased level of calcium and urea. Diarrhea was observed in some

members of group C and group D. Difficulty in breathing and movement was observed in the last week of the exposure, these behavioral symptoms. This is identical to Chavhan *et al.* (2011) and Soad *et al.* (2018). Mortality was also seen in group C, D, but in small numbers due to individual differences during adaptability and resistance to toxic effects.

Changes in Body Weights

Statistical results showed a significant decrease ($p < 0.05$) in body weight rate after treatment with dietary supplement compared with control group, the lowest body weight was (186.50 ± 11.50) g at group D for six weeks as shown in the table (1). due to the loss of appetite for the rat due to the high level of calcium and phosphate in the blood, especially in the last week, which leads to hypercalcemia due to the toxicity of vitamin D3 and thus led to reduced consumption of food based on the stored glycogen in the liver for a period of time and then the depletion of the glycogen in the liver led to its dependence on the glycogen stored in the skeletal muscle to release glucose to perform the functional requirements of the body and continued reliance on the muscle stock leads to a decrease in the amount of muscle mass and thus Low body weight (Soad *et al.*, 2018).

Table 1 : Effect of Dietary Supplement Vitamin D3 on Body Weights Rate After (3) and (6) Weeks

Group/Weight	Before	After 3 weeks	After 6 weeks
A(Control)	B219.75±10.73a	A264.50±13.52a	A267.25±13.12a
B	A229.50±5.57a	A237.50±5.60b	A229.50±5.45b
C	A236.25±5.18a	A228.75±8.43b	A216.75±11.27b
D	A231.75±10.54a	A222.25±11.60b	B186.50±11.50c
LSD	28.273		

Means with a different small letter in the same column significantly different ($P < 0.05$)

Means with a different capital letter in the same row significantly different ($P < 0.05$)

Biochemical Alterations

Statistical results of the present study showed a significant increase in the concentration of calcium and phosphorus in the serum of rats treated with vitamin D3 ($p < 0.05$) level compared to the control group and increases with increasing concentration and duration of dosage as it causes the toxicity of vitamin D3 which increases the level of calcium in the blood by increasing Resorption / mobilization of calcium from the bone, increased calcium absorption by the intestine and reduced calcium absorption by the kidneys, at the end is a high concentration of calcium level in the blood (Price and Buckley, 2001). The significant increase in plasma phosphorus levels in this study corresponds to the results of previous studies resulting from vitamin toxicity, It

also showed a significant increase in urea and creatinine concentration in the serum of exposed rats. These results correspond to the study of to Chavhan *et al.* (2011), who referred that the increase is due to the toxic effect of vitamin D3 in the kidneys. The rise in both urea and creatinine depends on the high rate of glomerular filtration. Or the increase due to the effectiveness of renal nephrons as a result of failure in kidney function (Mendelsohn *et al.*, 1999; Guyton and Hall, 2006). The increase in urea concentration due to nephritis is attributed to the current histological study. The present study also showed a significant decrease in PTH level compared with the control group due to high blood calcium level and increased vitamin D3 level which inhibit the secretion of this hormone as shown in the table (2).

Table 2 : Show the effect of vitamin D3 on the concentration of phosphorus, calcium, urea, creatinine, and PTH in serum albino rats (Average ± standard error) for 3 and 6 weeks.

LSD	Experimental group F for six weeks of doses Mean ±SD	Experimental group for three weeks of doses s Mean ±SD	Group	Parameter
3.6002	A 37.00±2.00 c	B 33.00±1.00 d, c	A(Control)	Urea (IU/L)
	A 48.50±0.50 a, b	B 26.50±1.50 d	Group B	
	A 46.50±0.50 b	B 38.00±1.00 b	Group C	
	A 50.00±0.00 a	A 46.00±1.00 a	Group D	
0.0588	A 0.41±0.01 b	A 0.36±0.04 c	A(Control)	Creatinine (IU/L)
	A 0.51±0.01 a	B 0.36±0.01 c	Group B	
	A 0.52±0.01 a	A 0.41±0.005 b, c	Group C	
	A 0.56±0.02 a	, B 0.47±0.01 a	Group D	

0.8625	B 3.20±0.10 c	A 4.11±0.01 b	A(Control)	Phosphors (IU/L)
	A 4.15±0.15 b	A 4.48±0.48 b	Group B	
	A 6.42±0.51 a	A 5.65±0.05 a	Group C	
	A 7.15±0.15 a	B 6.20±0.10 a	Group D	
0.5189	A 9.25±0.25 c	A 9.05±0.05 b	A(Control)	Calcium (IU/L)
	A 10.80±0.10 b	B 9.20±0.10 b	Group B	
	A 10.85±0.50 b	B 9.50±0.20 a, b	Group C	
	A 12.60±0.30 a	B 9.95±0.05 a	Group D	
0.2998	A 2.20±0.10 a	A 2.00±0.01 a	A(Control)	PTH (IU/L)
	B 1.65±0.05 b	A 2.05±0.05 a	Group B	
	B 1.40±0.02 b	A 1.70±0.10 b	Group C	
	A 1.02±0.02 c	A 1.25±0.05 c	Group D	

Means with a different small letter in the same column significantly different ($P < 0.05$)

Means with a different capital letter in the same row significantly different ($P < 0.05$)

Histological changes

Histological structure of the kidneys in the control group:

Microscopic examination of the kidney tissue sections in rats from the control group showed that the kidneys consist of the outer cortex region containing the urinary filtration

units Glomerulus and proximal and distal renal tubules and the kidneys are surrounded by a thin layer of connective tissue called capsule. The inner medulla region consists of ascending and descending limb of Henle loop as well as collecting tubes Fig. 1 (A,B)

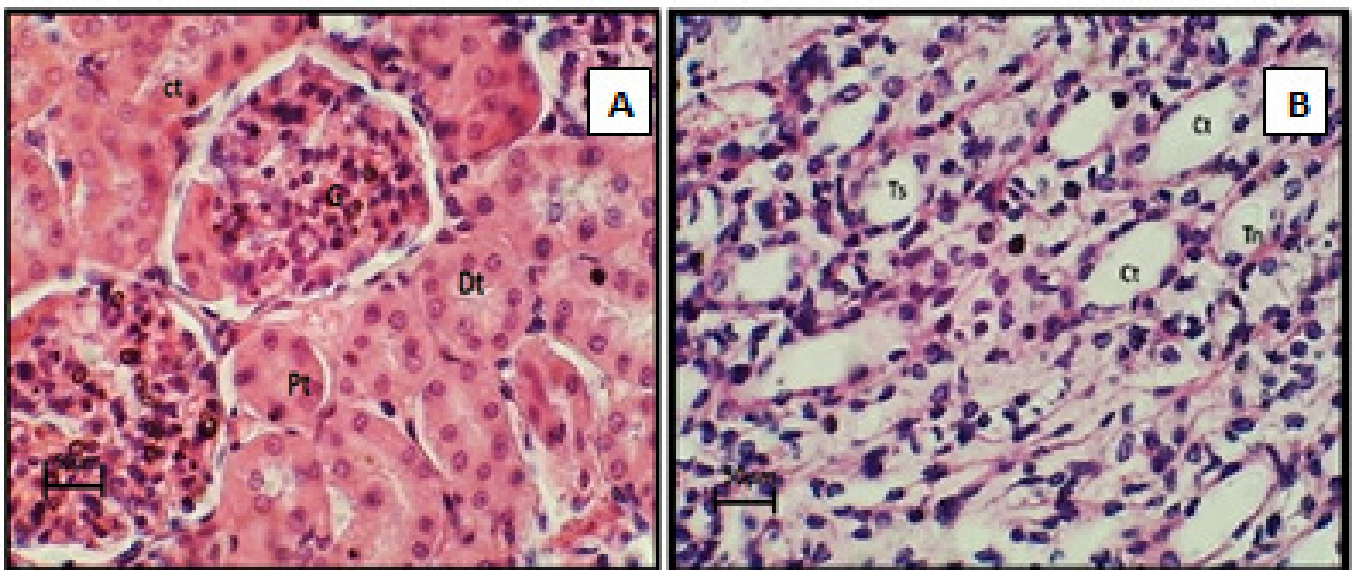


Fig. 1 :A- cross-section of rat kidney tissue in the control group in the cortex region show glomerulus (G), proximal convoluted tubule (PT), distal convoluted tubule (DT) and collecting tubules (CT) H&E staining(40x). B- medulla region show collecting tubules (Ct), descending tube of Henle loop (tn), and thick ascending arm of loop of Henle (Ts) (H&E) staining(40x).

Histopathological changes of the kidneys in the treated groups in concentrations, (5000, 7500, 1000) IU of the vitamin D3 supplement for three weeks:

Histological sections of the kidneys treated with a concentration of 5000 IU showed the appearance of hemorrhage as well as the vacuolation in the epithelium of the collecting tubules in the medulla region as in Fig.2 (A). The histological sections of the kidneys in the treated group with a concentration of 7500 IU showed the presence of necrosis in the affected areas and shrinkage in some urinary glomeruli as in Fig. 2(B) which may be due to the attempt of glomerular cells, especially Podocyte, to counter the toxicity

of the vitamin through hypertrophy with the expansion of capillary blood vessels as cellular responses due to the vitamin and the proportion of vitamin because the output is through the portfolio of Bowman and renal tubules (White *et al.*, 1984). Histological sections of the kidneys treated with a concentration of 1000 IU showed blood congestion in the tissue of the cells between the tubules collecting in the medulla region, also accompanied by infiltration of inflammatory cells and swelling of the urinary epithelium may be due to hydropic degeneration (Kumar *et al.*, 2007) as in Fig. 2 (C).

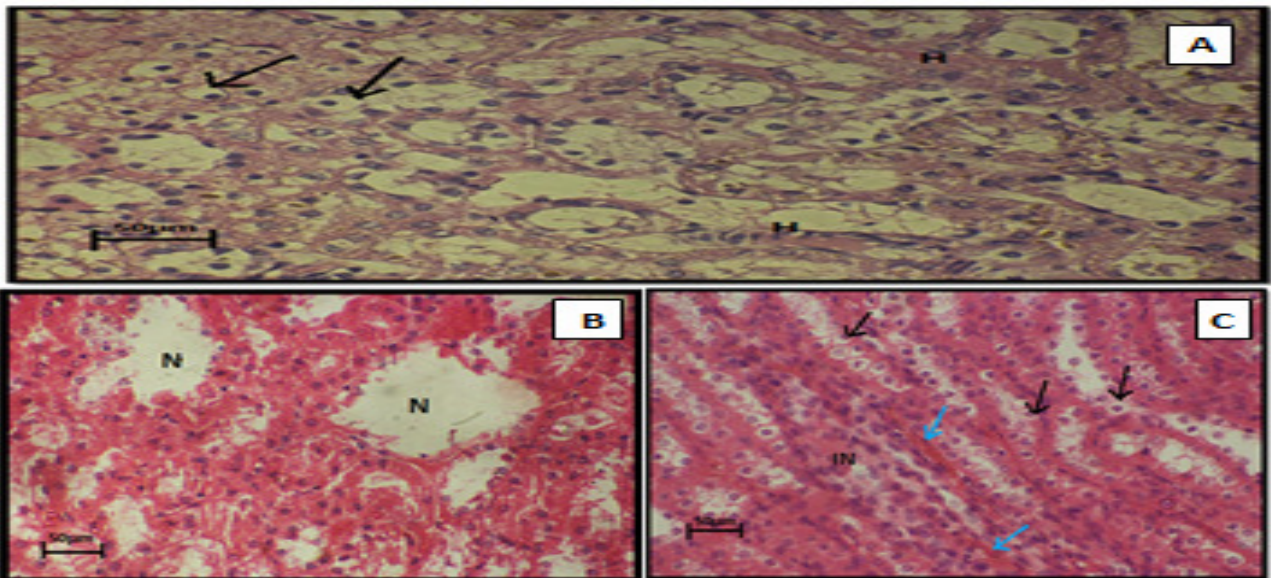


Fig. (2): **A-** cross section of rat kidney tissue treated with a concentration of 5000IU of vitamin D3 for three weeks shows hemorrhage(H) in renal tubules of the cortex region, vacuolation in epithelial cells of renal tubule (H&E) staining(40x) .**B-** cross section of rat kidney tissue treated with a concentration of 7500IU of vitamin D3 for three weeks necrosis(N) H&E staining(40x) .**C-** longitudinal- section in the rat kidney tissue treated with 1000IU concentration of vitamin D3 for three weeks shows infiltration of inflammatory cells (IN) and swelling of the renal tubule epithelial cells (→) and bloody congestion in the medulla region (→) H&E staining(40x) .

Histopathological changes of the kidneys in the treated group with a concentration (5000, 7500, 1000) IU of vitamin D3 supplementation for six weeks:

Histological sections of the kidneys in treated with a concentration of 5000 IU showed congestion among the renal tubules with the appearance of Cystic due to the occurrence of atrophy of the renal tubules and hemorrhage in the area of the cortex as in Fig.3 (A). The histologic sections of the kidneys in treated with a concentration of 7500 IU showed infiltration in inflammatory cells in the cortex area with simple blood congestion and necrosis of kidney tissue and swelling of the epithelial cells of renal tubules as in Fig.3 (B). Histological sections of the kidneys in treated with a concentration of 1000 IU showed bloody congestion with hyaline degeneration more than the previous concentrations

in the medulla region as in Fig. 3 (C), which gave a homogeneous structure with no cell boundaries. This pathological effect may be caused by cell damage, and the accumulation of abnormal proteins resulting from the decomposition of amino acids, especially immunoglobulin and carbohydrates (Stevens and Human. 2005). The atrophy of epithelial cells was accompanied by the occurrence of blood congestion and hemorrhage in the medulla region as well as the case of infiltration of inflammatory cells, these results correspond to the same in the study of Soad *et al.* (2018) and Kocher *et al.* (2010). Hemorrhage may be due to the persistent inflammation caused by the persistent vitamin effect, especially at 7500 IU concentration within 3 weeks of dosing (Mahmoud *et al.*, 1984). This is indicated to Chavhan *et al.* (2011) and Soad *et al.* (2018)

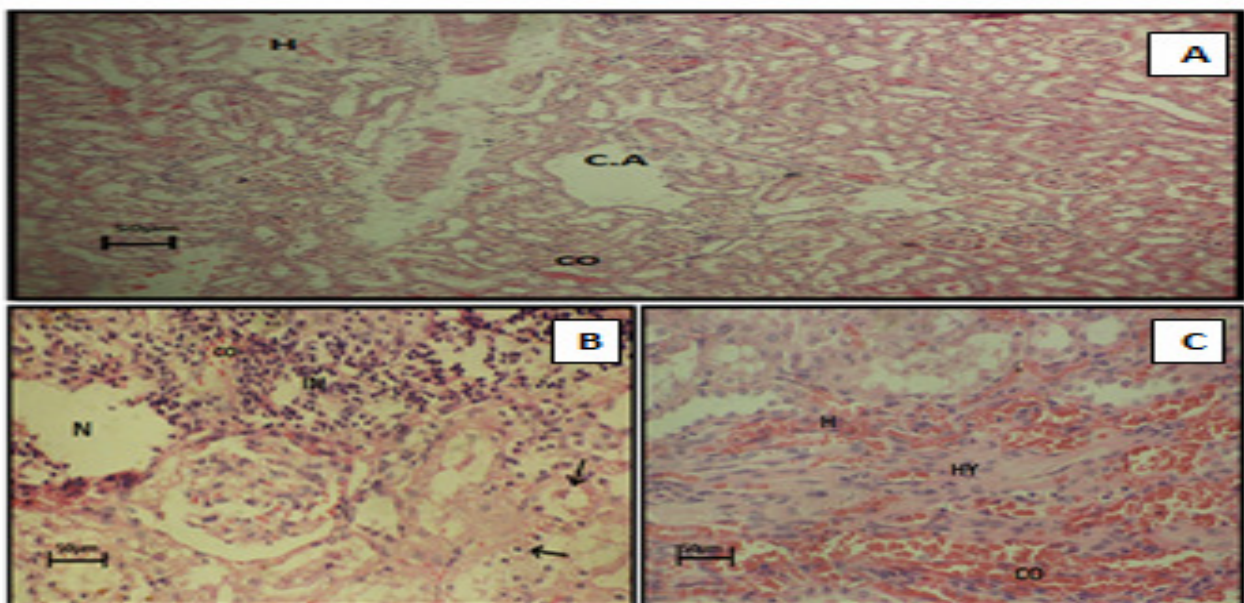


Fig. 3 : **A-** longitudinal-section of treated rat kidney tissue at 5000 IU concentration of vitamin D3 for six weeks shows the blood congestion (CO) among the renal tubules, hemorrhage (H) in the cortex and atrophy of the renal tubules (C.A) H&E staining (10x) .**B-** cross-section of treated rat kidney tissue at 7500 IU concentration of vitamin D3 for six weeks shows congestion (CO), infiltration of inflammatory cells (IN), necrosis in the cortex (N) , swelling of renal tubule epithelial cells (→) H&E staining (40x). **C-** cross section in kidney tissue treated with 1000 IU concentration of vitamin D3 for six weeks shows congestion (CO), hemorrhage (H), hyaline degeneration (HY) in the medulla region H&E staining (40x).

References

- Bancroft, J. and Stevens, A. (2010). *Theory and Practice of Histological. Technique.* 4nd ed. Churchill Livingstone, London.
- Chavhan, S.G. (2011). Clinicopathological studies on vitamin D3 toxicity and therapeutic evaluation of Aloe vera in rats. *Toxicology international*, 18.1: 35.
- Del-Valle and Heather, B. (2011). Dietary reference intakes for calcium and vitamin D. National Academies Press.
- Döneray, H. (2009). The clinical and laboratory characteristics of vitamin D intoxication in children. *Turkish Journal of Medical Sciences*, 39.1 (2009): 1-4.
- Guyton, A.C. and Hall, J.E. (2006). "Textbook of medical physiology". 10th ed. W.B.Saunders Company. Philadelphia : 104–121.
- Holick, M.F. and Vitamin, D. (2006). Its role in cancer prevention and treatment. *Prog Biophys Mol Biol.* 92: 49–59
- Kocher, D.K. (2010). Histopathological changes in vital organs of house rats given lethal dose of cholecalciferol (vitamin D3). *Indian Journal of Animal Research.* 2.3: 193-196.
- Kumar, V.; Abbas, A.K., Fausto, N. and Mitchell, R.N. (2007). *Robbins Basic Pathology.* 8th ed. Saunders Elsevier. PP:2,9,37,84, 292,632-634.
- Mahmoud, G.S. and Rasul, A.R. (1984). *General Veterinary Pathology.* Mosul University Press. 637.
- Marshall, Edward F. 1984. Cholecalciferol: a unique toxicant for rodent control.
- Mendelssohn, D.C.; Barrett, B.J.; Brownscombe, L.M.; Ethier, J.; Greenberg, D.E.; Kanani, S.D.; Levin, A. and Toffelmire, E.B. (1999). Elevated levels of serum creatinine : Recommendations for management and referral. *CMAJ.* 161(4).
- Patel, S. (2007). Association between serum vitamin D metabolite levels and disease activity in patients with early inflammatory polyarthritis. *Arthritis & Rheumatism: Official Journal of the American College of Rheumatology*, 56.7 : 2143-2149.
- Price, P.A. and Buckley, J.R. (2001). William MK. The amino bisphosphonate ibandronate prevents vitamin D induced calcification of arteries, cartilage, lungs and kidneys in rats. *J Nutrition*, 131: 2910-5.
- SAS S. AS.2010.SAS/STAT. (2005). *Users Guide for Personal Computer.* Release 9.13.SAS Institute, Inc., Cary, N.C.
- Soad, S.A.; Sawsan, H.M. and Ramziyyah, M. (2018). The Effects of Hypervitaminosis D in Rats on Histology and Weights of Some Immune System Organs and Organs Prone to Calcification *International Journal of Pharmaceutical and Phytopharmacological Research (eIJPPR).*
- Stevens, A. and Lowe, J.H. (2005). *Histology.* 3rd ed. Elsevier Mosby, Philadelphia. 296-298.
- White, W.T.; Harrison, L. and Dumas, J. (1984). Nitrofurantoin unmasking peripheral neuropathy in type2 diabetic patient. *Arch Intern Med.* 18: 680-687